

Successful combined spinal-epidural anaesthesia for EXIT procedure in foetal goitre associated with maternal Graves' disease: a case report

Siti Nadzirah binti **Saad**¹, Nazuha binti **Mohd Najid**², Shahir Asraf bin **Abdul Rahim**¹

¹*Department of Anaesthesiology & Intensive Care, Sultan Ahmad Shah Medical Centre @IIUM, Kuantan, Pahang, Malaysia;* ²*Department of Anaesthesiology & Intensive Care, Hospital Sultanah Bahiyah, Alor Setar, Kedah, Malaysia*

Abstract

The ex-utero intrapartum treatment (EXIT) procedure is a rare, but lifesaving intervention performed during a Caesarean section to enable controlled foetal airway and other intrapartum procedures. Its main goal is to secure the foetal airway while maintaining utero-placental circulation, preventing airway obstruction at birth. The EXIT procedure is preferred in conditions such as congenital high airway obstruction syndrome and airway compression from neck or thoracic masses. This case report details the management of a 22-year-old primigravida with Graves' disease whose foetus was diagnosed with an anterior neck mass consistent with thyroid goitre. Antenatal ultrasound and magnetic resonance imaging confirmed a lesion anterior to the trachea. After multidisciplinary discussion between the obstetrician, obstetric anaesthesiologist, and paediatric otorhinolaryngology teams, an emergency Caesarean section with an EXIT procedure was performed at 37 weeks and 3 days. Anaesthesia was provided using a combined spinal-epidural technique. Nitroglycerin facilitated uterine relaxation, and phenylephrine maintained maternal hemodynamic stability. Foetal tracheal intubation was successfully performed

Correspondence: Shahir Asraf bin Abdul Rahim, Department of Anaesthesiology & Intensive Care, Sultan Ahmad Shah Medical Centre (SASMEC @IIUM), Kuantan, Pahang, Malaysia.

E-mail: drshahirasraf@iium.edu.my

under direct laryngoscopy while placental circulation was preserved. This case highlights the success of combined spinal-epidural anaesthesia in avoiding a potential high-risk airway complication to the mother and secure the foetal airway while oxygenating the foetus via the placenta.

Keywords: airway management, combined spinal-epidural anaesthesia, ex-utero intrapartum treatment (EXIT), foetal goitre; Graves' disease

Introduction

Foetal goitre is a rare but clinically significant prenatal finding, most often secondary to maternal Graves' disease resulting from the transplacental transfer of thyroid-stimulating antibodies.¹ The ex-utero intrapartum treatment (EXIT) procedure facilitates controlled foetal interventions by providing simultaneous maternal and foetal anaesthesia while utilizing targeted uterine relaxation to maintain placental circulation intact and avoid the risk of premature separation.² Initially described in 1981 for congenital diaphragmatic hernia,³ its application has expanded to conditions such as congenital high airway obstruction syndrome and airway compression by foetal neck masses.^{2,3} General anaesthesia with high-dose volatile agents (2–3 minimum alveolar concentration) remains the conventional approach for uterine relaxation.^{4,5} However, neuraxial anaesthesia has been increasingly reported as an alternative, offering hemodynamic stability and avoidance of maternal airway manipulation.^{4,6–8} We describe a case of successful management using combined spinal-epidural (CSE) anaesthesia for EXIT procedure, managing a rare foetal goitre secondary to maternal Graves' disease, addressing the dual high-stakes risks of maternal thyroid storm and anticipated difficult maternal airway.

Case presentation

A 22-year-old primigravida with a body mass index of 25 kg/m² presented with reduced foetal movements at gestational age (GA) 32 weeks. She had a known history of Graves' disease diagnosed in 2019 and was initially followed up at a district hospital before defaulting the following year. She subsequently continued her follow-up at our centre for poorly controlled hyperthyroidism secondary to Graves' disease. Her first thyroid function test (TFT) at our centre revealed a very low thyroid-stimulating hormone (TSH) level of < 0.01 mIU/L (normal range 0.3–5.0 mIU/L) and a very high free thyroxine (FT4) level of 30.26 pmol/L (normal range 12–22 pmol/L) with symptoms of palpitation, heat intolerance, and insomnia. The endocrinology team

Table 1. Maternal serial thyroid function tests and antithyroid medication regime from mid-gestation through the postoperative period

Gestational age	TSH (mIU/L)	FT4 (pmol/L)	T3 (pmol/L)	Antithyroid regime
6/2/23 @17 weeks	< 0.08	75		T carbimazole 15 mg OD T propranolol 20 mg PRN
13/6/23@32 weeks	< 0.01	30.26		T carbimazole 20 mg OD T propranolol 40 mg BD
23/7/23@36 and 5 days	< 0.01	30.1		T carbimazole 40 mg OD T propranolol 40 mg BD
29/7/23 @37 weeks and 2 days	0.01	22.36	10.07	T carbimazole 40 mg OD T propranolol 40 mg TDS
POD 2				T carbimazole 30 mg OD T propranolol 40 mg BD
POD14				T carbimazole 25 mg OD T propranolol 40 mg BD
POD 27	< 0.01	18.25		T carbimazole 20 mg OD T propranolol 40 mg BD

TSH: thyroid-stimulating hormone (normal range, 0.3 to 5.0 mIU/L); FT4: free thyroxine (normal range, 12 to 22 pmol/L); T3: triiodothyronine (normal range, 3.1 to 6.8 pmol/L); POD: postoperative day; OD: Omni die; PRN pro re nata; BD: Bis die; TDS: Ter die sumendum

was consulted, and her antithyroid regimen was optimised further with carbimazole and propranolol, which were initially started from the previous hospital. Serial TFTs (Table 1) were monitored, and medication doses were adjusted accordingly. Toward the later part of pregnancy, her hyperthyroid symptoms improved significantly. At GA 37 weeks and 2 days, laboratory results showed normalised thyroid biochemistry with TSH 0.1 mIU/L, FT4 22.36 pmol/L, and T3 10.07 pmol/L. Clinically, her blood pressure (BP) and heart rate (HR) were well controlled, with systolic BP less than 130 mmHg and HR less than 100 beats per minute, with no hyperthyroid and obstructive symptoms.

At 32 weeks' gestation, ultrasound foetal assessment by the obstetric team revealed an anterior foetal neck swelling measuring 4.3 cm x 5.1 cm. An urgent magnetic resonance imaging (MRI) of the foetus (Fig. 1) demonstrated an irregularly shaped lesion at the anterior neck, 4.3 cm x 3.5 cm, with a possible thyroid origin. In anticipation of a compromised airway at birth, a multidisciplinary team comprising obstetricians, obstetric anaesthesiologists, paediatric otorhinolaryngologists, and an endocrinologist collaborated to discuss on the delivery plan and to prepare for

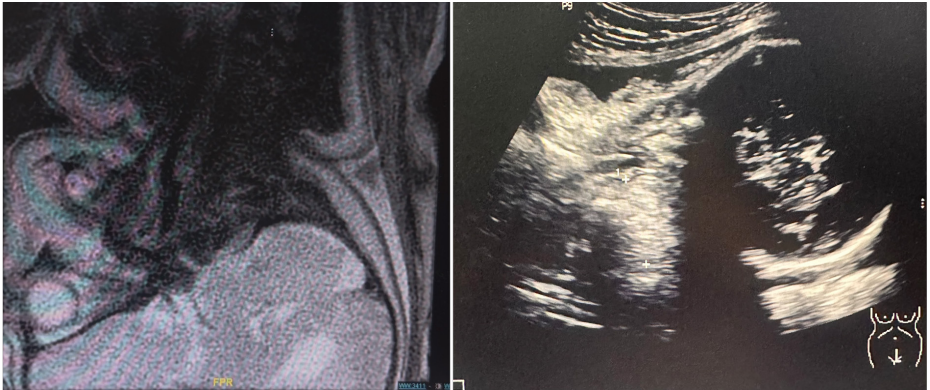


Fig. 1. (Left) MRI scan of the foetus showed an irregularly shaped lesion in the anterior neck region. A complementary ultrasound scan of the foetus (Right) showed an irregular echogenic lesion, possibly of thyroid origin. The airway appears to be patent on both imaging studies.

potential airway interventions, including readiness for an EXIT procedure.

Preoperative consultation was conducted to reduce the patient's anxiety. Echocardiogram before surgery revealed a left ventricular ejection fraction of 60% with no significant cardiac abnormality. CSE was considered to provide surgical anaesthesia, offering the flexibility to extend the block if necessary. The surgery was planned at GA 37 weeks and 3 days, with the presence of a multidisciplinary team of experts.

In the operating room, standard monitoring was applied with pulse oximetry, electrocardiogram (ECG), and non-invasive BP. An arterial line for continuous arterial pressure monitoring and two peripheral intravenous lines (16-G) were inserted before induction. Her initial vital signs were BP 142/81, HR 89, and pulse oxygen saturation 97% on room air. To reduce anxiety and enhance comfort, the patient listened to green music through headphones intraoperatively. General anaesthesia and airway medications were prepared for immediate conversion if the block proved to be inadequate or foetal distress developed. The patient was placed in a sitting position, and CSE was performed at L3-4 intervertebral space using an Espocan® set (B. Braun, Melsungen, Germany), utilizing an 18-G epidural needle for epidural space identification and a 27-G spinal needle for subarachnoid entry. After the clear cerebrospinal fluid was aspirated, 10 mg hyperbaric bupivacaine 0.5% with 10 mcg of fentanyl was given into the subarachnoid space, and an epidural catheter was inserted to 9 cm at the skin. She was positioned supine with the left lateral tilt to avoid aortocaval compression. The cephalad spread of the sensory blockade reached the T4 dermatome within 10 minutes of the intrathecal injection of 0.5% hyperbaric bupivacaine.

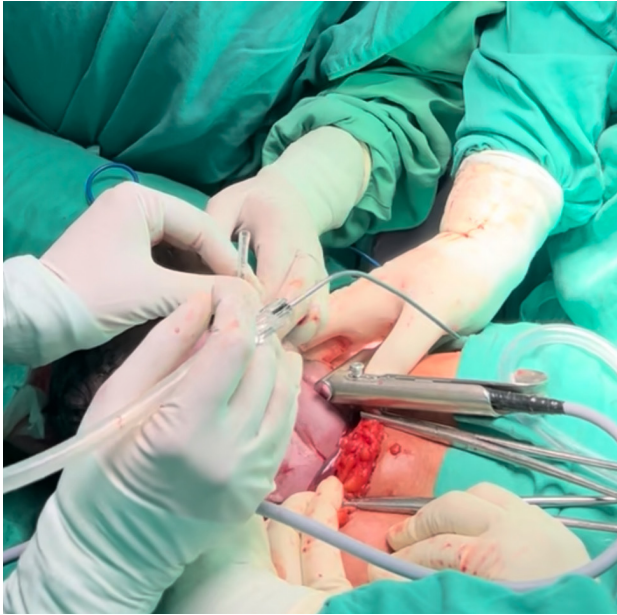

Fig. 2. Tracheal intubation of the partially delivered foetus was performed under direct laryngoscopy during the ex-utero intrapartum treatment procedure while maintaining placental support.

A bolus of intravenous phenylephrine 100 mcg was given once, followed by infusion at 0.03–0.04 mcg/kg/min to maintain maternal systolic BP of 100–120 mmHg. Nitroglycerin 0.5–0.6 mcg/kg/min infusion was started pre-uterine incision to achieve uterine relaxation. The skin incision to uterotomy required 10 minutes. At the time of uterine incision, the obstetrician confirmed that the uterus was fully relaxed. During EXIT, once the foetal head and shoulder were delivered, tracheal intubation was performed under direct laryngoscopy with a Parsons 8.0-cm laryngoscope using a 3.5 mm endotracheal tube preloaded on a 2.7-mm telescope, and the tube was anchored at 9 cm (Fig. 2). The position and placement of the tracheal tube were confirmed under direct laryngoscopy. Once the foetal airway was secured, the umbilical cord was clamped and cut. Time from uterine incision to cord clamp was 5 minutes. After delivery of the foetus, the infusion of nitroglycerin and phenylephrine was stopped. A bolus of intravenous oxytocin 5 units was given, followed by an infusion of 20 units/L. Epidural morphine 3 mg was administered for postoperative analgesia. Total fluid given intra-operatively was 1200 ml, with an estimated blood loss of 300 ml. The total time elapsed from starting the anaesthetic procedure to the end of the operation was 79 minutes. The neonate was transferred to the neonatal intensive care unit for mechanical ventilation and was successfully extubated on day 2 of life.

Discussion

Foetal goitre is an uncommon prenatal finding, most frequently associated with maternal autoimmune thyroid disease, particularly Graves' disease, due to transplacental passage of thyroid-stimulating or blocking antibodies.¹ Its clinical significance lies in the risk of neonatal airway obstruction at birth, which can lead to hypoxia and severe morbidity if not anticipated. Early detection by ultrasonography and foetal MRI facilitates comprehensive assessment of airway patency and multidisciplinary planning for delivery. In this case, although imaging demonstrated a patent trachea, the presence of a large anterior neck mass prompted preparation for an EXIT procedure to ensure a secured neonatal airway was achieved prior to cord clamping.

The EXIT procedure facilitates controlled establishment of the foetal airway through specialized interventions including direct laryngoscopy, rigid or flexible video laryngeal tracheoscopy, or surgical tracheostomy while preserving continuous foeto-placental gas exchange. This approach provides a critical physiological window for managed intervention, ensuring foetal oxygenation remains intact until the airway is secured and placental support is no longer required.^{2,3} General anaesthesia is traditionally preferred for EXIT because volatile agents can provide effective uterine relaxation at a minimum alveolar concentration > 2 .⁹ However, this technique carries inherent maternal risks, including airway difficulty, haemodynamic instability, and an increased incidence of postpartum haemorrhage due to uterine atony induced by high doses of volatile anesthetics.^{2,4,9} Moreover, excessive concentrations of inhalational agents have been linked to foetal bradycardia.⁴

As the preferred modality for Caesarean delivery, neuraxial anaesthesia avoids the risks associated with maternal airway instrumentation, which is particularly advantageous in high-risk patients with thyromegaly. In addition, this approach also suppresses the sympathetic response, thereby reducing the likelihood of a thyroid storm in a parturient with poorly controlled Graves' disease.^{6,8} When neuraxial anaesthesia is employed, surgical tocolysis is effectively achieved with intravenous nitroglycerin, which offers a rapid onset and prompt reversibility due to its short half-life.^{3,7,8,10} While these properties allow for precise titration, nitroglycerin carries inherent risks of maternal hypotension and protracted uterine atony, necessitating vigilant hemodynamic monitoring and the use of titrated vasopressor support.

In this case, a CSE technique was chosen to provide rapid and reliable anaesthesia while strategically avoiding airway manipulation and minimizing sympathetic activation that could precipitate a life-threatening thyroid storm. Surgical tocolysis was successfully achieved using intravenous nitroglycerin for uterine relaxation, while maternal hemodynamic stability was meticulously maintained through a titrated phenylephrine infusion. While maintaining continuous placental support,

the otorhinolaryngology team successfully intubated the foetal airway via tracheal intubation, resulting in uneventful postoperative recoveries for both the mother and neonate.

This case reinforces emerging evidence supporting neuraxial anaesthesia as a safe and effective alternative to conventional general anaesthesia for EXIT procedures. For selected parturients, particularly those where general anaesthesia carries excessive risk, optimal outcomes are predicated on early prenatal diagnosis, meticulous preparation, and a highly synchronized multidisciplinary collaboration between the obstetric, anaesthesia, and neonatal specialty teams.^{2,7}

Conclusion

This case illustrates the successful application of CSE technique for an EXIT procedure in a parturient with Graves' disease while mitigating the risks of maternal thyroid storm and airway complications. Careful planning and coordination allowed regional anaesthesia to provide a safe and stable environment, successfully balancing maternal safety with controlled physiological requirements for establishing the foetal airway. This experience supports the consideration of neuraxial anaesthesia as a viable alternative to general anaesthesia in selected EXIT cases, emphasizing the importance of individualized anaesthetic strategy and close multidisciplinary collaboration.

Declarations

Informed consent for publication

Written informed consent for publication of clinical details and images was obtained from the patient.

Competing interests

None to declare.

Funding

None to declare.

Acknowledgements

The authors would like to acknowledge the multidisciplinary team involved in the care of the patient.

References

1. Léger J. Management of fetal and neonatal graves' disease. *Horm Res Paediatr.* 2016;87(1):1–6. doi:[10.1159/000453065](https://doi.org/10.1159/000453065)
2. George RB, Melnick AH, Rose EC, Habib AS. Case series: Combined spinal epidural anesthesia for Cesarean delivery and ex utero intrapartum treatment procedure. *Can J Anesth.* 2007;54(3):218–222. <https://doi.org/10.1007/bf03022643>
3. Karanth SK, Tran KM. Anaesthesia for foetal interventions. *Anaesthesia Tutorial of the Week (ATOTW 532).* 2024. <https://doi.org/10.28923/atotw.53>
4. Kumar K, Miron C, Singh SI. Maternal anesthesia for EXIT procedure: A systematic review of literature. *J Anaesthesiol Clin Pharmacol.* 2019;35(1):19–24. https://doi.org/10.4103/joacp.joacp_302_17
5. Wang W, Pei L, Zhang Y, Chen W, Liu J, Jiang Y, et al. Neuraxial anesthesia in ex utero intrapartum therapy for parturients with fetal congenital diaphragmatic hernia: a prospective observational study. *Int J Obstet Anesth.* 2022;52:103599. <https://doi.org/10.1016/j.ijoa.2022.103599>
6. Dinges E, Ortiz J, d'Oria V, Bernstein K, Landau R, Chollat C, et al. Multimodal general anesthesia approach for ex utero intrapartum therapy (EXIT) procedures: Two case reports. *Int J Obstet Anesth.* 2019;38:142–145. <https://doi.org/10.1016/j.ijoa.2018.08.009>
7. Gaffuri M, Raffaeli G, Bullejos Garcia EE, Perugino G, Cassardo O, Persico N, et al. The ex-utero intrapartum treatment procedure: A narrative review. *Front Pediatr.* 2025;13:1601963. <https://doi.org/10.3389/fped.2025.1601963>
8. Bouchard S, Johnson MP, Flake AW, Howell LJ, Myers LB, Adzick NS, et al. The EXIT procedure: experience and outcome in 31 cases. *J Pediatr Surg.* 2002;37(3):418–426. <https://doi.org/10.1053/jpsu.2002.30839>
9. Pattaravit N, Karnjanawanichkul O, Benjhawaleemas P. Successful management of Ex-Utero intrapartum treatment procedure for Cystic Teratoma under Sole Spinal Anesthesia: An anesthetic challenge case report. *J Health Sci Med Res.* 2022;40(6). doi:10.31584/jhsmr.2022899
10. Benonis JG, Habib AS. Ex utero intrapartum treatment procedure in a patient with arthrogryposis multiplex congenita, using continuous spinal anesthesia and intravenous nitroglycerin for uterine relaxation. *Int J Obstet Anesth.* 2008;17(1):53–56. <https://doi.org/10.1016/j.ijoa.2007.01.007>